

Daniel P. Keenan, DVM
Ron McAlister, DVM
Lynsey D. Makkreel, DVM



TENDON INJURIES

Tendons are the strap-like structures that attach muscles to the bones on which they act. Most tendons are short and rarely damaged. However, the long tendons of the limbs are very vulnerable to damage during exercise or as a result of direct trauma. The flexor tendons are most important and it is these that are discussed below.

Where are the tendons situated?

The flexor tendons are the deep digital flexor tendon (DDFT), and superficial digital flexor tendon (SDFT), which run down the back of the leg from the level of the knee or hock. The SDFT ends at the pastern, the DDFT ends on the lower surface of the coffin bone. Injury to the SDFT is more commonly known as "bowed tendon". At the back of the knee, in the region of the hock and at the level of the fetlock and upper pastern, the tendons are enveloped by a fluid filled sheath. Several strong, short, annular ligaments help to keep the tendons in place in areas of high movement such as joints.

The tendons themselves are composed of longitudinally arranged bundles of fibres. Blood supply to tendons is poor compared to muscles and other tissues.

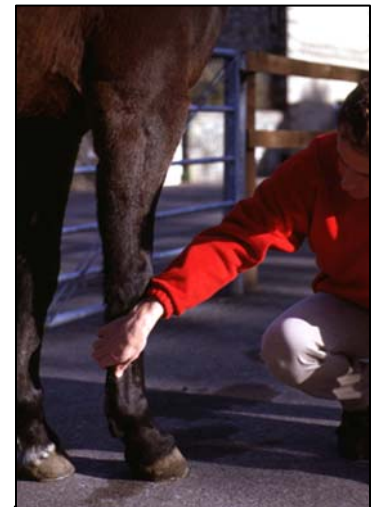
What are the different types of tendon injury?

Damage to flexor tendons most commonly occurs during exercise when the limb is overextended, the fetlock drops down dramatically and the tendon is overstretched. Over stretching of tendons can occur with any type of exercise but is more common during fast work, work on unlevel ground or work involving jumping at speed. The risk is much greater in an unfit horse and horses that have a metabolic disorder called Cushing's disease. The degree of damage can range from minor, with little fiber damage to very severe with total tendon rupture occurring.

A traumatic blow to a tendon may result in slight bruising or more severe damage, possibly even tendon rupture. Sharp trauma such as a cut can also result in anything from minor damage to severing of the tendon. Injuries involving tendon sheaths are very serious as infection in these structures is potentially life threatening.

What are the first signs of tendon injury?

Damage to a tendon causes inflammation, heat and swelling. Minor fiber damage leads to slight enlargement of the affected part which will feel warmer than the corresponding area on the other limb. Mild strains may not cause lameness. In severe damage, the limb will become very painful and swollen and the horse may be severely lame. If the SDFT is ruptured, the fetlock may be slightly dropped and if the horse ruptures both the SDFT and DDFT then the fetlock will drop and the toe will be tipped up. If a tendon sheath becomes



Veterinarian examining a horse's tendon for signs of injury



A bowed tendon

infected, the horse will also be very lame. Infections of the tendon sheath typically require surgical debridement and lavage to clean up the infection and prognosis following this is still only regarded as fair.

How can tendon injuries be diagnosed?

If you suspect that your horse has a tendon injury, you should call your veterinarian immediately. A clinical examination will confirm or eliminate your concerns. Your veterinarian will look for signs of thickening of the affected tendon(s), heat and pain on palpation. It can be difficult to assess the extent of damage by look and feel alone. Ultrasonographic examination allows visualisation of the structure of the tendon and any damage. It also allows assessment of healing processes.

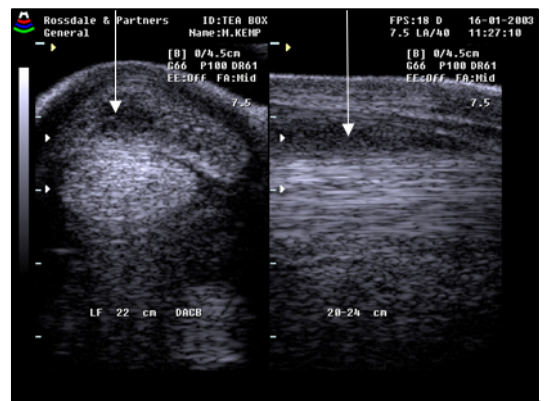
What treatments are available?

There are several treatments for tendon injuries but none is guaranteed to result in permanent soundness. Damaged tendon heals by producing irregularly arranged fibers which are weaker than normal linear tendon and re-injury is common. In the early stages, anti-inflammatory treatment such as the application of cold, support bandaging and anti-inflammatory drugs are useful. Total stall rest is vital. Most tendon injuries require at least 3 months of rest and hand walking. Repeat tendon scans are invaluable for assessing healing before exercise levels are increased. In many horses, it is a year before they are fit to compete again.

Attempts have been made to speed up healing and to improve the quality of the repair tissue by injecting substances into the tendon itself. Most recently A-cell, VetStem and Platelet Rich Plasma have been used with moderate success. There is no current conclusion as to which is the most effective product and it seems to be a matter of veterinarian preference as to which gets used. Another therapeutic modality that is currently being used is Shockwave therapy. High frequency sound waves are directed at the affected region of the tendon. This procedure which has been shown to reduce pain and inflammation and potentially help speed healing is typically repeated three times, two to three weeks apart.

The prognosis for horses with complete tendon rupture is very poor. If the rupture is due to a wound in the area surgery can sometimes be performed to try and bring the ends of the tendon closer together. These animals are then placed in a cast following surgery to try and reduce the amount of motion in the affected area. Non-traumatic ruptures may partially heal but it is unlikely the horse will ever be sound again.

After a period of rest and at upon advise by your veterinarian, your horse should be introduced to a gradually increasing program of exercise which should eventually include trotting and very steady cantering. One must be cautioned at this point that a horse may not be able to return to its previous level of work.



Ultrasound images of a horse's tendon injury

Daniel P. Keenan, DVM

Ron McAlister, DVM

Lynsey Makkreel, DVM

165 Third Street ♦ Bordentown, New Jersey 08505 ♦ 609-291-0535 ♦ fax 609-291-8899

www.KeenanMcAlister.com ♦ KME@KeenanMcAlister.com