

Daniel P. Keenan, DVM  
Ron McAlister, DVM  
Lynsey D. Makkreel, DVM

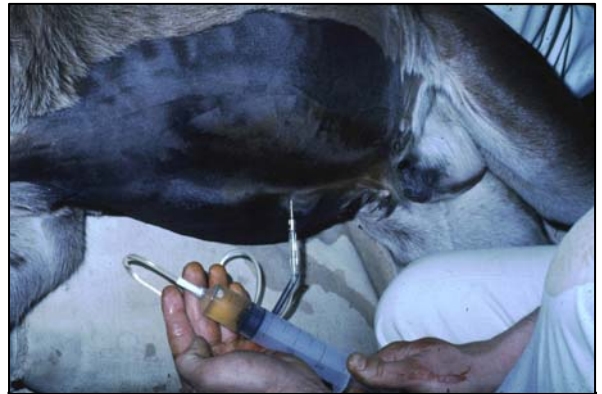

## RUPTURED BLADDER

This is one of the conditions that affect young foals during their first few days of life. It is potentially life threatening. Some cases occur when the full urinary bladder wall tears in response to high pressure during delivery whereas others result from incomplete development (closure) of the bladder wall leaving a hole in the wall. Both conditions result in leakage of urine into the abdomen (uoperitoneum). Another type of hole formation, resulting in uoperitoneum occurs as a result of infection of the urachus and is not a truly ruptured bladder. The urachus is the tube that runs from the tip of the bladder to the umbilicus (navel) prior to birth, draining fetal urine into the placental fluids. Infection can result in rupture of the urachus before it fully closes and consequent leakage of urine into the abdomen.

### ***What are the symptoms?***

When bladder rupture occurs at birth, signs usually develop within 2 or 4 days of life. Colts are affected more often than fillies. If leakage of urine follows infection of the urachus, signs can develop later, but within a month of birth. Symptoms are caused by the accumulation of urine in the abdominal cavity rather than it being voided normally. This results in pressure on the diaphragm and toxemia as the waste products in the urine are reabsorbed into the foal's blood. Affected foals usually pass smaller-than-normal volumes of urine and adopt a fairly characteristic straining posture with the legs stretched out and the back flat. The abdomen becomes progressively more distended. The foal usually appears depressed and goes off nursing. Respiratory rate becomes more rapid and breathing can become quite labored particularly when the foal lies down as pressure builds up against the diaphragm. The heartbeat can become weak and rapid and cardiac arrhythmias can develop due to abnormalities in electrolyte levels in the blood. If left untreated, collapse and death usually follow.



**Urine being drained from a foal's abdomen**

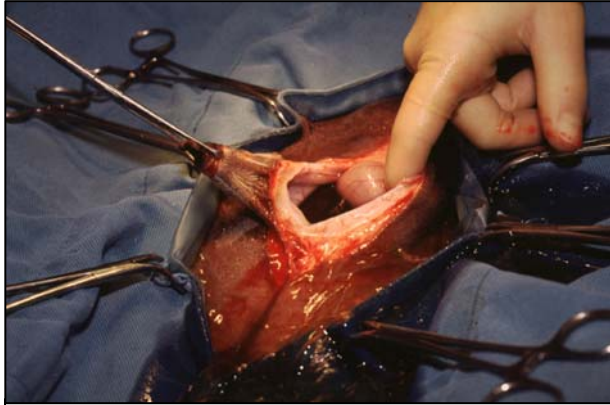
### ***How is the condition diagnosed?***

The clinical signs of ruptured bladder can initially be vague. Correct diagnosis requires recognition of clinical signs and the results of one or more test procedures. Ultrasound examination of the abdomen may demonstrate a large volume of free fluid and is now the most efficient means of making an early diagnosis. Blood tests can be useful to look for increased levels of toxic substances. A sample of peritoneal fluid can be taken from the abdomen and tested or compared to a blood sample to confirm that it is urine. Other tests involve injection of a dye into the bladder via the urethra to see if it then appears free in the abdomen.

Where rupture follows infection of the urachus, or if other problems such as septicemia (blood infection) exist, clinical signs may be more complex. Ultrasound examination is the most useful tool when looking for infection or abscess of the urachus.

### ***What treatment is available?***

When a ruptured bladder or urachus is diagnosed, surgery is the cure. Prior to surgery, it is essential to provide medical treatment to correct electrolyte imbalances, treat concurrent infection and restore fluid levels if dehydration is present. The abdomen is usually drained to remove the toxic urine. This is called 'peritoneal lavage'.



**Ruptured bladder of foal during surgical**

Once the foal's condition has been stabilized, surgery is performed to remove damaged and/or infected bladder and urachal tissue and then to close the defect. Antibiotics are usually given for several days afterwards to remove infection. The foal can be returned to its dam immediately and should be allowed to nurse normally. If it does not nurse, supportive treatment such as intravenous fluids and/or administration of mare's milk or milk replacer by stomach tube may be needed. In any case, early diagnosis and referral for surgery gives the best chance for success.

### ***Are there any long-term effects?***

Normally, provided an accurate diagnosis is made early and once the foal is prepared correctly and the bladder defect is repaired successfully, recovery is rapid and complete. Rarely, adhesions may occur between the bladder and other intra-abdominal organs causing colic symptoms. Full recovery will depend on successful treatment of any other conditions that may also be present such as septicemia and joint ill.