

Daniel P. Keenan, DVM  
Ron McAlister, DVM  
Lynsey D. Makkreel, DVM

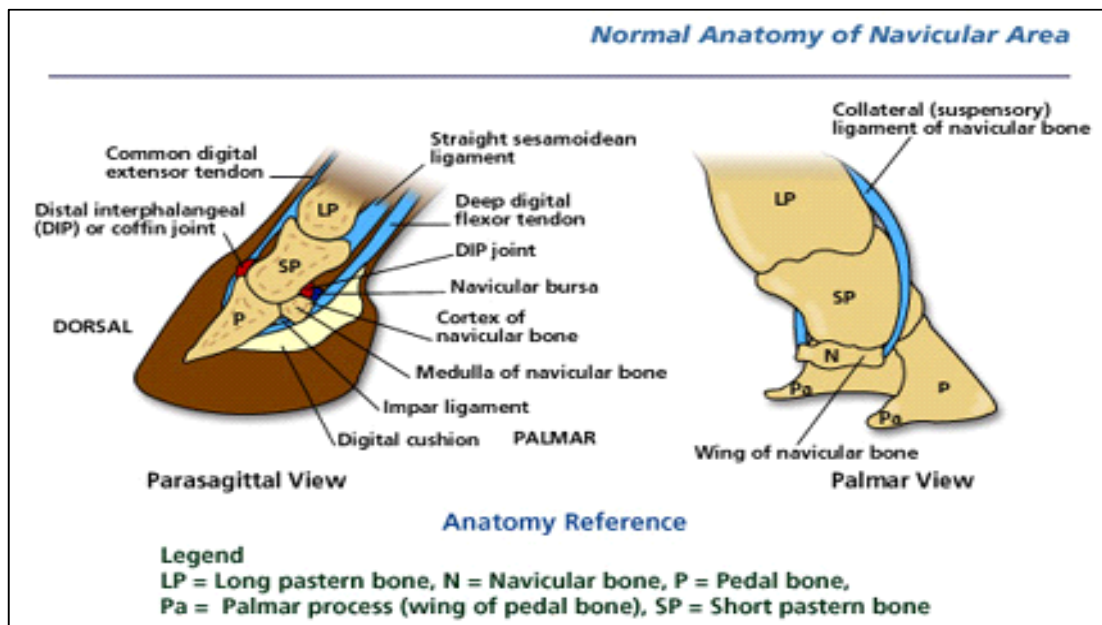


## NAVICULAR SYNDROME

Navicular disease is really a group of related conditions affecting the navicular bone and associated structures in the foot. There are several possible causes of pain in and around the navicular bone.

### Anatomy of the navicular region

The navicular bone is a small flattened bone, which lies across the back of the coffin joint. It attaches to the pedal (coffin) bone via a short strong ligament (the impar ligament) and to the pastern joint by suspensory ligaments. The deep digital flexor tendon runs over the lower surface of the navicular bone, which acts somewhat like a pulley and between these lies a small pocket of fluid, the navicular bursa, which acts like a cushion between the tendon and its pulley.



### **What causes navicular disease?**

At present, the exact primary cause of Navicular Syndrome is not known. Damage to the navicular bone may occur due to interference with blood supply or trauma to the bone. Damage can occur to the deep flexor tendon, navicular bursa, or navicular ligaments all resulting in pain and lameness. Conformation and unbalanced trimming contribute greatly to the disease. It is somewhat inherited, either directly or in the inherited conformation of the feet that makes a horse more prone to navicular disease.

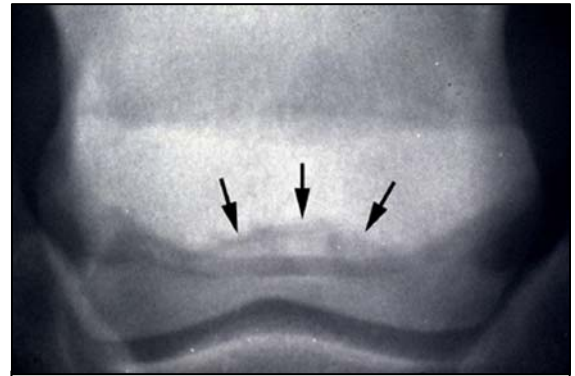
### **What are the symptoms?**

Navicular disease affects the front feet of horses causing a low grade bilateral lameness, which usually progresses slowly. The lameness might only occur from time to time or when the horse is exercised on hard ground or in a small circle. In some cases, one foot is affected more than the

other, causing an obvious lameness. Affected horses may stand with the more painful foot in front placed of the other (pointing).

### **How is navicular disease diagnosed?**

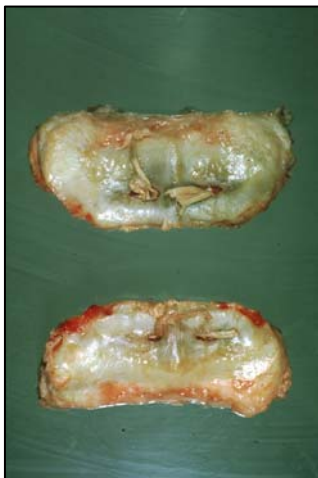Diagnosis is based on a combination of history, symptoms, nerve blocks and radiography. A history of intermittent low grade or recurrent lameness is suggestive of navicular disease. Affected horses often appear to place the toe down first, as if trying not to put weight on their heels (in contrast to laminitis), and the lameness is worse on the inside leg on a circle. Injection of local anaesthetic (nerve block) around the nerves sensitizing the back half of the foot and/or into the navicular bursa will improve or alleviate the lameness associated with navicular disease. Some cases also improve when the coffin joint is blocked. Radiographs may reveal damage to the navicular bone but bone changes can be difficult to interpret, as there are differing opinions on what is normal. Navicular syndrome can exist without demonstrable radiographic abnormality and magnetic resonance imaging (MRI) may reveal injury to the impar or other ligaments or soft tissues.



Radiograph of navicular bone showing chronic change at lower boarder

### **What treatments are available?**

Navicular disease can be treated and managed, but rarely cured. Corrective trimming and shoeing is imperative to ensure level foot fall and foot balance. Often a rolled toe egg bar shoe is used to encourage early break over at the toe and good heel support. Medication such as phenylbutazone will elevate pain in many cases and enable work to be resumed. Long term treatment with substances such as isoxsuprine and aspirin may improve blood supply to the navicular bone and improve the condition of the bone.



Post mortem navicular bones showing chronic damage

Long term desensitization of the back of the foot can be achieved by performing a neurectomy to cut the heel nerves. This treatment should only be considered as a last resort and then only in full recognition of the implications. Post operative complications are common and include rupture of the deep flexor tendon, painful inflammation of the cut nerve endings (neuromas) and damage to the foot which goes unnoticed by horse and owner. The nerves often grow back and the lameness returns within 1-2 years of surgery. Treatment options should be discussed in detail with your veterinarian.

### **Can navicular disease be prevented?**

Horses with all foot shapes can develop navicular disease. Nevertheless, maintaining good foot balance and heel support can help to prevent many foot lamenesses. Prepurchase examinations can help identify affected horses before you buy them.