

KERATOMA

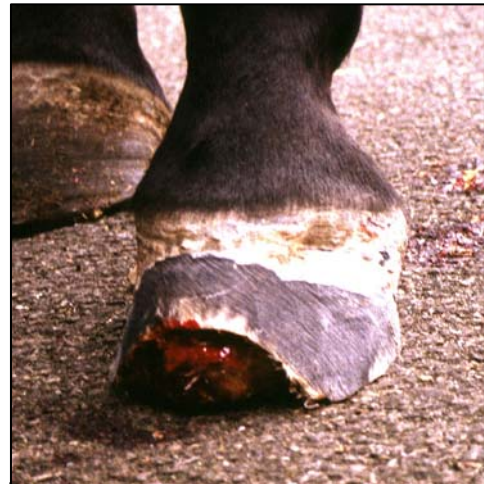What is a Keratoma?

A keratoma is a rare benign tumor of the inner layer of keratin-producing epidermal hoof wall cells which forms inside a horse's foot. As the tumor slowly grows, it expands and separates the hoof wall laminae, causing pain and lameness. The tumor grows downwards, because space for growth is restricted inside the rigid hoof structure. Keratomas tend to develop more commonly at the toes and any of the feet may be affected. Two forms of keratoma are recognized:

- 'Cylindrical'-shaped keratomas, which run in the hoof wall directly towards the sole.
- More discrete 'spherical'-shaped keratomas, most often towards the toe.

What causes a keratoma?

Being a tumor (a cancer), the precise cause of this abnormal hoof cell growth is unknown, but some cases appear to follow injury to, or inflammation of, the coronary band. Fortunately these tumors are benign and do not spread to other areas of the horse's body.



Keratoma visible as tumor mass after removal of overlying hoof wall.

How is a keratoma diagnosed?

The first thing to be noticed may be signs of bulging of the hoof wall at the coronet. Lameness develops, to a speed and degree depending upon the size, position and speed of growth of the tumor and may appear as sudden onset or chronically-progressive lameness.

On examining the sole of the horse's foot, the white line is distorted and it deviates towards the frog behind the tumour. The horse may show pain when hoof testers are applied over the tumour. When the tumor grows down to the sole, the white line separates.

Occasionally, infection tracks up between the distorted laminae and pus may be found at the white line of the wall/sole junction or from the coronary band.

Radiographics of the foot show the tumor as a characteristic-looking area of well-defined loss of pedal bone density caused by tumor formation and bone resorption.

Precise confirmation of the diagnosis can be achieved by examining a processed microscopic section (histological examination) of the removed tissue.

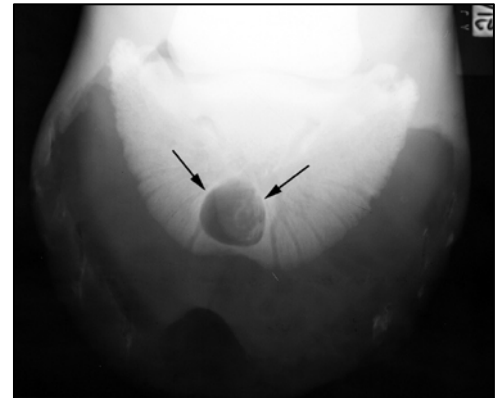
How can a keratoma be treated?

The tumor and overlying hoof wall requires surgical removal under local or general anaesthesia. Parallel cuts are made in the hoof wall on either side of the tumor, and the section of hoof wall is

carefully peeled away from the underlying sensitive laminae up to the level of the coronet. The keratoma tissue often has a texture like parmesan cheese.

The surgical wound is then packed with sterile gauze soaked in antiseptic solution and the foot is bandaged or preferably fitted with a hospital plate. A hospital plate is an aluminium plate specially made to fit over a specially made shoe, with accommodating screws, so that the plate can be removed and replaced for wound treatments. The plate protects the surgical wound and dressings. The horse is treated with antibiotics.

Thereafter, the bandage and antiseptic gauze pack is changed every 2-3 days until a layer of dry protective cornified laminae have formed. The affected foot is shod with a full-bar shoe with clips either side of the hoof wound, to help stabilise the hoof wall defect. The horse is kept in clean dry conditions until the wound is completely healed.



Radiograph of horse's foot showing a keratoma

How can a keratoma be prevented?

Being a tumor, methods of prevention are unknown, but injury to or inflammation of the coronary band should be rapidly and efficiently treated.

Caution

Growth of new epidermal laminae to restore the hoof wall is a slow process (0.6 cm per month), but with patience and careful management the prognosis for soundness and return to athletic activity is usually good. When the tumor grows down to the sole, separating the white line, infection may gain access, so be aware for abscess formation. Keratomas are benign tumours, that is, they do not metastasise or spread to other parts of the body, but sometimes recur at the same site.

Rarely, more than one keratoma may be present in the same foot.