

Daniel P. Keenan, DVM  
Ron McAlister, DVM  
Lynsey D. Makkreel, DVM



## FRACTURES

A fracture is a crack or break in a bone. Just about every bone in the body can be fractured but fractures of the bones of the limbs are of major importance in horses. Fortunately many, but not all, fractures can now be repaired if diagnosed and managed appropriately at an early stage.

### ***What types of fracture can occur?***

The severity of a fracture depends upon several factors:

Which bone and which part of the bone is involved.

The type of fracture.

The size, age, temperament and use of the horse or pony.

Whether other important soft-tissue structures are involved.

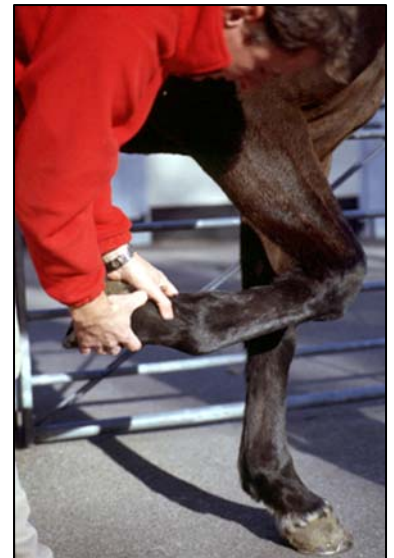There is a range of terms used to describe fractures, based upon visible and x-ray examinations:

**Simple fractures** have only one fracture line whereas **comminuted fractures** have multiple fracture lines and pieces of bone have become separated. Depending on the bone and site involved, simple fractures are usually easier to repair than comminuted ones.

**Incomplete fractures** are cracks that involve only one cortex (side) of the bone and therefore, although painful, remain stable unless they become **complete fractures**, when the bone fragments separate. In human orthopedics, these fractures are most commonly seen in children with soft, immature bones and are then often referred to as '**greenstick**' fractures.

**Stress fractures** are small incomplete fractures, which most commonly occur in young athletic horses. They may involve any of the limb bones but the radius and tibia are the most common sites. They sometimes involve multiple bone cracks from a central focus and are then sometimes called '**star**' fractures. These are initially painful but the pain often resolves relatively quickly before healing is complete. If not diagnosed as fractures and if the horse is exercised too soon, they extend to become complete fractures, with catastrophic results. These fractures are now diagnosed by nuclear bone scanning (scintigraphic examinations) and are treated and managed accordingly. The incidence of catastrophic radial, tibial and other bone fractures in performance horses has reduced accordingly.

**Compound (open) fractures** involve broken overlying skin, sometimes with the broken bone end clearly visible, whereas in **closed fractures**, the overlying skin is intact. Compound fractures are usually contaminated with environmental debris and infected with their microorganisms, making successful treatment and repair more difficult and therefore the prognosis less good and sometimes hopeless.



**Veterinarian examining  
foot and pastern**

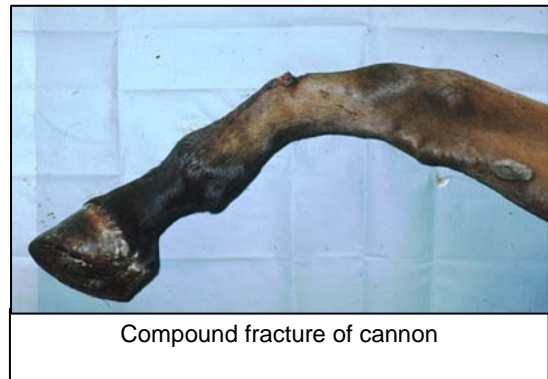
**Chip fractures** involve very small pieces of separated bone whereas larger fragments are called **slab fractures**. Chip and slab fractures inside joints often need removal to discourage the formation of arthritis and degenerative joint disease. Outside joints, they may heal themselves with rest and time. Large slab fractures, inside or outside joints, sometimes need surgical replacement with screw fixation. Small separated chip fractures freely-floating inside joints are sometimes called '**joint mice**'.

**Displaced fractures** are those where the bone fragments have moved apart and there is a gap between them, whereas **non-displaced fractures** have maintained their normal positions and only a crack is visible. Depending on the bone and site involved, non-displaced fractures are usually easier to repair than displaced ones.

**Avulsion fractures** are where a piece of bone is pulled away by the abnormally strong action of an attached tendon or ligament. As damage to soft tissue structures is also involved, these fractures may be difficult to heal.

Fractures that involve joints usually have a much poorer prognosis than those that do not, because arthritis and degenerative joint disease are common secondary problems causing problems after the fracture has healed.

The description of a fracture may involve several of these terms, e.g. a compound displaced comminuted fracture of the cannon bone.



#### ***What are the most common fractures seen?***

The most common equine fractures involve the bones of the lower limbs. Fractures usually occur either as a result of direct trauma from a fall, kick or knock or during strenuous exercise. The most common fractures are:

**Fractures of the pedal bone.** These most commonly occur if the horse kicks out at a wall or lands on an irregular surface. If the fracture does not involve the coffin joint, many heal well with prolonged rest and the application of a bar shoe. If the fracture involves the coffin joint, the outlook is guarded. Surgical screw fixation may be used to help some of the larger fractures to heal, especially those that involve the coffin joint.

**Fractures of the pastern** most commonly involve the long pastern bone (first phalanx, P1). These are usually longitudinal and extend down from the fetlock joint. They may be incomplete or complete, displaced or non-displaced, simple or comminuted. Some simple, non-displaced fractures repair well with bandaging and rest but most can be repaired more rapidly and with less risk of secondary complications, using surgical screw fixation. Comminuted and compound pastern fractures carry a poor prognosis for future athleticism although some can be salvaged for breeding purposes.

**Sesamoid bone fractures.** The small sesamoid bones at the back of the fetlock joint act as a form of pulley for the suspensory ligaments. Fractures of these bones occur quite commonly in young foals, often as avulsion fractures at the attachments of the suspensory ligaments. They may cause pain and

lameness with fetlock enlargement but many go unnoticed until radiographic examinations of the fetlocks are taken later for another reason. When they occur in adult horses, fractures of the sesamoid bones can result in chronic or recurrent lameness. In foals, small apical (top of the bone) chip fractures usually carry a good prognosis with appropriate treatment (rest and supportive bandaging) but where the fragments are large or basal (bottom of the bone) the outlook is less good. This is because the sesamoid bones are imbedded in the suspensory ligament, which constantly pulls on the fragments, in addition to the pain from the damage to the ligament itself.

**Fractures of the cannon bones** are also usually longitudinal and may extend into the fetlock joint. The same comments therefore apply as for pastern fractures above. Occasionally a transverse (side-to-side) fracture occurs as a result of a fall or kick. The prognosis for these fractures is poor although some have been successfully repaired using surgical fixation involving both plates and screws.

**Carpal (knee) bone fractures.** Most of these are chip or slab fractures, which occur on the front or side margins of the bones within the carpal joints. If small, they may occur without causing obvious signs of lameness although most result in pain and joint distension (the joint fills with fluid containing painful inflammatory mediator chemicals). Many chip fractures respond well to rest, helped sometimes with the injection of anti-inflammatory medicines into the affected joint. Some bone chips require surgical removal and this can now usually be achieved with arthroscopic surgery more quickly and less traumatically than with arthrotomy (conventional surgical opening of the joint). Slab fractures usually require either removal or surgical screw fixation, depending on their size and site.

**Fractures of splint bones** are very common. They can occur during exercise or after a kick or fall. Most heal with rest but always leave a lump ('splint') where the healing callous forms. Occasionally a splint fracture does not heal (non-union) and it is necessary to remove the lower portion of the affected bone to alleviate the associated pain or discomfort.

**Fractures of the radius (forearm bone) and tibia (thigh bone).** Incomplete or stress fractures are common in these sites in young performance horses and full recovery is possible with rest. Early accurate diagnosis by nuclear bone scan (scintigraphic) examination is essential to confirm the diagnosis and to monitor repair before exercise is resumed, or these fractures may be converted into complete ones. Complete fractures carry a very poor prognosis.

**Olecranon (elbow) fractures** are usually the result of a kick and are therefore often compound and comminuted. In simple, closed, non-displaced fractures, healing can occasionally occur with rest alone although best results are obtained following surgical fixation by inserting a plate and screws to pull the fragments together. Compound and/or comminuted fractures carry a poorer prognosis but surgical repair can be attempted.



**Radiographic examination of a hock**

**Fractures of the pelvis.** These are a common cause of hindlimb lameness in young performance horses. Most start as incomplete stress fractures and will fully heal if diagnosed early and given complete rest and adequate time. Early accurate diagnosis by nuclear bone scan (scintigraphic) examination is essential to confirm the diagnosis and to monitor repair before exercise is resumed. Some pelvic fractures are mistakenly diagnosed as muscle injuries. Unfortunately complete, displaced pelvic fractures often necessitate euthanasia on humane grounds.

### ***How are Fractures Diagnosed?***

Detailed clinical examination is the most important starting point. Most limb fractures cause a degree of lameness although this can vary from mild to non-weight bearing depending on the fracture type and site. There is usually some swelling over the affected area and there is pain on palpation or manipulation of the bone. Occasionally, crepitus (rubbing of the fractured bone ends) can be felt. In stress fractures and some incomplete fractures there might be no external signs except for slight lameness. For accurate diagnosis of most fractures radiographic examinations are essential. For more subtle fractures, nuclear bone scan examinations can help to localize the fracture. Ultrasound scans can be useful for fractures of bones in the upper limbs where radiography may not be possible.

### ***What treatments are available?***

All fractures require reduction (restored anatomic relationships), stability (no movement between the fragments) and rest to allow repair. For some simple and incomplete types of equine lower limb bone fractures, bandaging, casts or splints can provide adequate stability. In more complex fractures, especially of the higher limb bones where bandages, casts and splints cannot be successfully employed, surgical fixation, using screws, plates, pins or wires are needed to hold the fragments together. Small chip and slab fractures inside joints may be removed successfully using arthroscopic surgery. Choice of treatment technique will depend on site and type of fracture, age and use of the horse and financial considerations. Cases must be discussed fully with your veterinarian so that all options can be evaluated and suitable decision for the individual case can be made.

In spite of all attempts, some complex fractures, particularly compound fractures and those that involve joints and upper limb bones, remain irreparable and require euthanasia to be performed on humane grounds. Unlike humans, who can be instructed to rest in bed or use crutches to bear no weight on the leg, horses need to be able to use their legs immediately after attempts at surgical repair. This sometimes puts impossible stresses on newly operated fractures.

---

Daniel P. Keenan, DVM

Ron McAlister, DVM

Lynsey Makkreel, DVM

165 Third Street ♦ Bordentown, New Jersey 08505 ♦ 609-291-0535 ♦ fax 609-291-8899

www.KeenanMcAlister.com ♦ KME@KeenanMcAlister.com