

Daniel P. Keenan, DVM
Ron McAlister, DVM
Lynsey D. Makkreel, DVM



ENDOSCOPY

What is Roaring?

Some horses often make an abnormal noise (a high pitched 'whistle' or less commonly a lower pitch 'roar') when they breathe in at fast exercise. This is usually due to a paralysis or partial paralysis (paresis) of the larynx, an apparatus at the back of the throat. It is important to be able to distinguish these noises from other respiratory noises caused by other throat problems such as infections or simply lack of fitness. The larynx is a complex valve located at the back of the throat just above the trachea (windpipe). The larynx is made of cartilage, muscle and nerves and is covered by a mucous membrane. It, and particularly the arytenoid cartilages which form the front of the larynx, act as a valve to prevent food from being inhaled when the horse eats (it closes tightly during swallowing) while allowing the maximum amount of air to enter the lungs during exercise (it opens fully when the horse breathes in). Also, it is the organ of voice production.

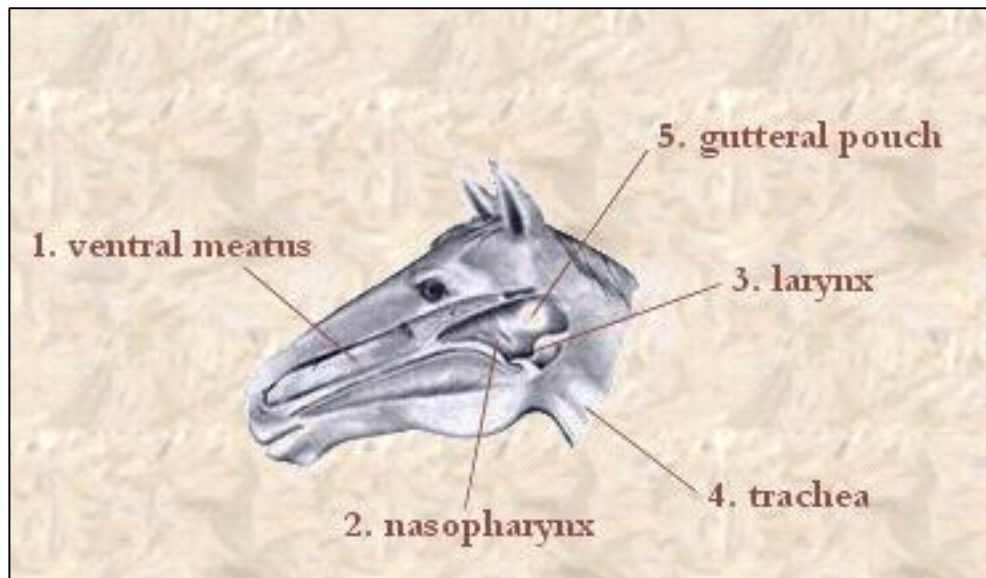


Diagram showing picture of horse's larynx.

What is an endoscopic examination?

An endoscope is an instrument designed to look inside the body, in this case, into the respiratory systems. An endoscope consists of a bundle of optical fibers inside a waterproof rubber tube. Bright light produced by a connected light source is transmitted along the fibers to illuminate the area of the horse to be examined and then back along the fiber bundles to the eyepiece. An endoscopic exam



Longeing a horse

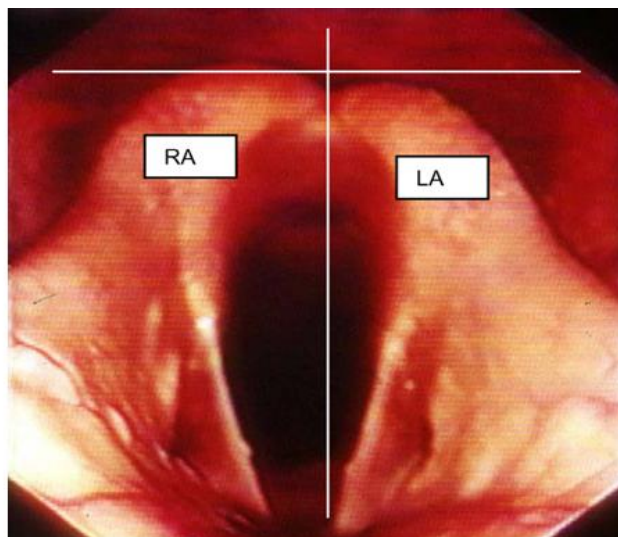
of the respiratory track can be used to look specifically at the structure and function of the larynx. There is an important and relatively common condition of horses that causes the muscles of the larynx to function improperly because the nerves that supply them become diseased. This means that the larynx cannot open fully during inspiration. If the larynx cannot be opened fully when the horse is at exercise, the horse becomes short of breath and its athletic performance is often significantly diminished. This disease has several names including **laryngeal hemiplegia**, recurrent laryngeal neuropathy and laryngeal paralysis or paresis. Colloquially the condition has been called 'whistling' or 'roaring', depending on the type of abnormal noise that the horse makes when it breathes in. The left side of the larynx is most commonly affected, although right-sided cases do occasionally occur.

How is laryngeal hemiplegia diagnosed?

The condition is suspected when the horse makes an abnormal inspiratory (roaring or whistling) during strenuous exercise or performs poorly in competition, especially if it "fades" near the end of a race. The diagnosis is confirmed by an endoscopic examination, and watching the movement of the arytenoid cartilages.

What causes laryngeal hemiplegia?

Sometimes injury or infection to the neck, or a reaction to an intramuscular injection can cause roaring, but the vast majority of the time the cause is unknown. Usually, the horse has normal function when young and the paralysis develops as the horse matures. It is thought that the nerve which controls the function of the larynx becomes slowly damaged. This nerve, the **recurrent left laryngeal nerve**, starts at the base of the brain and curves around to reach the larynx. The nerve on the right travels more directly along the throat to reach the muscles of the larynx. The nerve on the left side follows a considerably longer and more tortuous path; travelling down the neck and into the chest where it wraps around part of the heart before coming all the way back up to the larynx. This long pathway is thought to predispose the left nerve to damage by simple stretching. This is why over 90% of paresis is on the left side. Also, roaring is much more common in long necked horses such as Thoroughbreds. It has been estimated that over 89% of draft horses are roarers, but, since these giants do not compete at speed, it is not a problem for them.



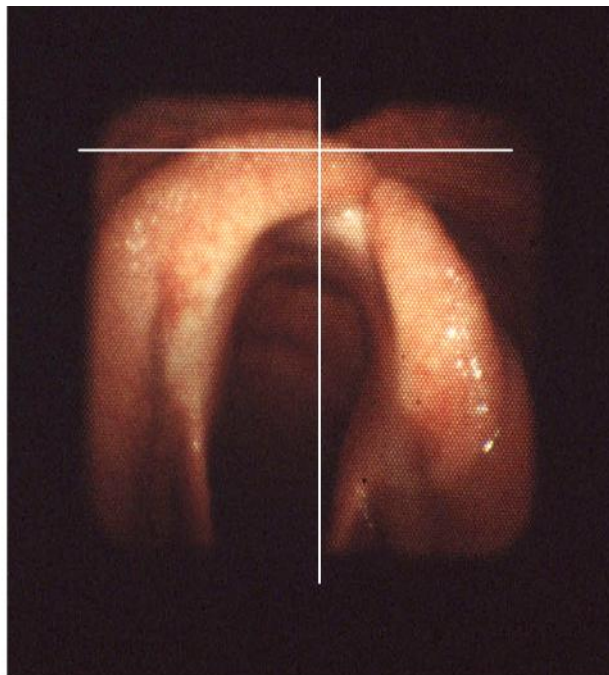This is the larynx seen through the endoscope as the horse breathes in. The horse's left is on the right of the picture. The left arytenoid cartilage (LA) can be seen to be slightly lower than the right arytenoid cartilage (RA), when compared using the guide lines superimposed on the image. This is described as incomplete abduction.

This larynx was graded as "2 out of five", a common finding in normal racing thoroughbreds

When the larynx is viewed through an endoscope, the left arytenoid cartilage is carefully examined while the larynx opens and closes as the horse breathes in and out. Paralysis is seldom complete and it can be difficult to recognise early signs. Even in normal horses, the left arytenoid cartilage sometimes moves more slowly than the right one. It may not move at precisely the same time or through the same range of motion as the right-sided cartilage. Sometimes the left side opens fully but closes slightly before the opposite side. The movements of the arytenoid cartilages are therefore described in terms of synchrony and symmetry.

A commonly used system grades a horse's larynx 'out of five':

1. A totally normal horse in which all the movements of the larynx occur simultaneously and in complete harmony. Both sides of the larynx open fully and hold their open position as required.
2. This larynx can do all the movements required, but sometimes the left side moves a little later than the right side. When viewed with the horse breathing quietly, it looks a little 'lop-sided' because there is 'resting asymmetry'. Most Thoroughbred horses fall into this category.
3. This larynx shows premature weakening, i.e. its left side opens fully but sags downwards whilst the right side remains fully open.
4. The left side of the larynx cannot open (abduct) fully.
5. The larynx shows total or almost total paralysis, i.e. the left side cannot move at all.



This horse has a paralysed left arytenoid cartilage. The cartilage is nearly vertical and barely moves at all even when the horse is made to breathe deeply

The appearance of the larynx will vary slightly, even in the same horse, between examinations. This means that during one examination, the larynx shows no signs of abnormality but at another examination it may show some premature weakening. The larynx may therefore be graded as a 'two out of five' during one examination and a 'three out of five' at the next, apparently 'jumping groups'.

Laryngeal disease is progressive. A purchaser may have bought a horse with a 'three out of five' larynx one year only for it to deteriorate sufficiently to require surgery twelve months later. This is not an uncommon occurrence.

Horses are commonly and routinely examined at rest, whereas the real test of its functional capacity comes when it is galloping at full speed, as in a race. The larynx works at its best (and worst) when the horse is performing at maximum effort. Endoscopic examinations can be performed on a high-speed treadmill with a horse exercising at full speed and results sometimes show abnormalities that are not detectable when the horse is breathing quietly. Paradoxically, some horses that perform poorly and make abnormal inspiratory noises at exercise on and off the treadmill have no demonstrable laryngeal abnormalities.

Daniel P. Keenan, DVM

Ron McAlister, DVM

Lynsey Makkreel, DVM

165 Third Street ♦ Bordentown, New Jersey 08505 ♦ 609-291-0535 ♦ fax 609-291-8899

www.KeenanMcAlister.com ♦ KME@KeenanMcAlister.com