

CANKER

What is canker?

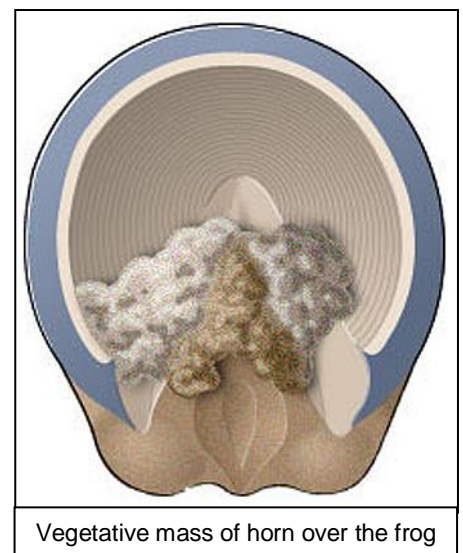
Canker is a rare but troublesome infection of the horn of the foot which results in the formation of a soft, moist, disintegrating growth of horn. It most commonly affects the hind feet and is usually in horses kept in wet climates or in large draught type horses. It is predisposed by long heel conformation which results in deep sulci (clefts) adjacent to the frog.

What causes canker?

The exact cause is unknown, but bacterial or fungal infection is suspected. It starts as invasion of the epidermal horn of the foot, starting around the frog and extending to the sole and wall. In advanced cases infection may enter the underlying sensitive laminae of the hoof.

How is canker diagnosed?

In the early stages, a foul-smelling, moist, vegetative mass of horn is seen, although lameness is rarely encountered. The characteristic fragile, fronds of horn growth start at the back of the frog and are sometimes covered with a crusty overgrowth. In advanced cases, a cauliflower-like proliferative growth may be seen along the heels, bars, sole and hoof wall and lameness may develop at this stage. Affected horses may stamp the affected foot, reflecting irritation. If deeper tissues are involved, there may be swelling of the pastern and lower limb. Most horses with canker are lame. Radiographic examinations may be required to determine the extent of the damage to the bony structures of the foot and the collateral cartilages (sidebones).



How is canker treated?

Conservative treatment starts with cleaning up the sole, sulci and frog, removing all abnormal, dead and infected tissues. Sometimes this has to be done under general anesthesia. The cleaned hoof is then packed with sterile gauze soaked in antiseptic solution and the foot is bandaged. The horse will begin long term systemic antibiotics.

Afterwards, you must ensure clean, dry stable conditions and the bandage and antiseptic gauze pack must be changed every 2 days until there is no more discharge and the tissues appear healthy and healing. The horse must be kept out of wet and muddy conditions until the wound is completely healed. This can take weeks to months. When recovered, the affected foot should be reshod and any hoof malformation should be gradually corrected. Often, surgical intervention is required. Under general anesthesia, all or the abnormal tissue is removed. The systemic antibiotics and bandages are still required. Canker often recurs, and not all cases can be cured. The prognosis for complete resolution is poor for long-standing cases with spread to the sole involving deeper tissues, because recurrence is common, especially in those horses with hoof deformity. Sometimes, long term management is the best that can be hoped for.

How can canker be prevented?

Prevention is always better than cure and canker can be usually be avoided by good stable management and regular foot care and inspection. You should stable your horse in clean dry conditions and you should exercise your horse regularly. Your horses' feet should be regularly trimmed and shod, in order to avoid the development of long heel conformation and to keep the frog healthy. Even with meticulous care, cases of canker can still occur. Early detection of the problems greatly improves the prognosis.

Daniel P. Keenan, DVM Ron McAlister, DVM Lynsey Makkreel, DVM
165 Third Street ♦ Bordentown, New Jersey 08505 ♦ 609-291-0535 ♦ fax 609-291-8899
www.KeenanMcAlister.com ♦ KME@KeenanMcAlister.com